



Preliminary Report :

**Percutaneous Trigger Finger Release
using Korat-Satja1 (KS1) Instrument**

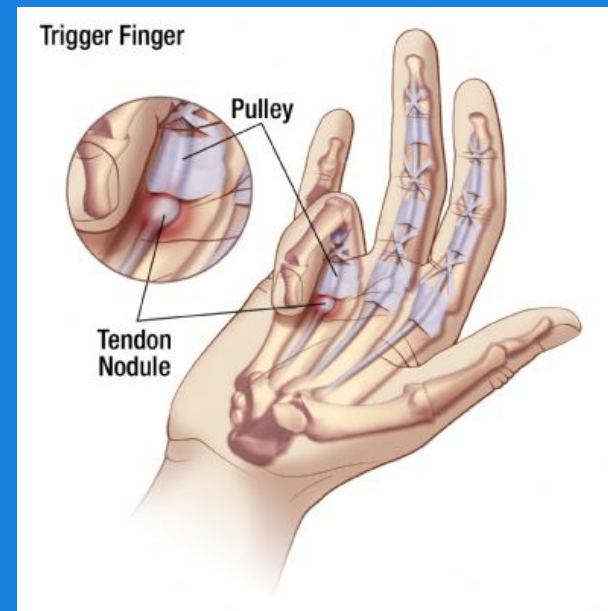
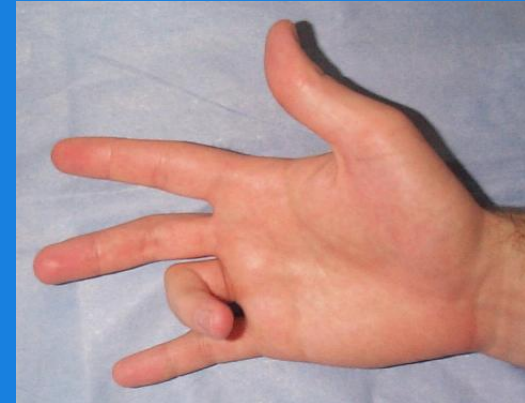
**Satja Thoedpraisan M.D.
Department of Orthopedic Surgery Maharat
Nakhon Ratchasima Hospital**



Trigger finger

common

- Green's Classification 4 stage
 1. Pre triggering
 2. Active
 3. Passive
 4. Contracture





Treatment

1. **Conservative** : rest, medication, and steroid injection.
2. **Open release (standard)**
 - Success rates reported up to 100 %.
 - Complications : infection, digital nerve injury, scar tenderness and joint contractures.
3. **Percutaneous release**

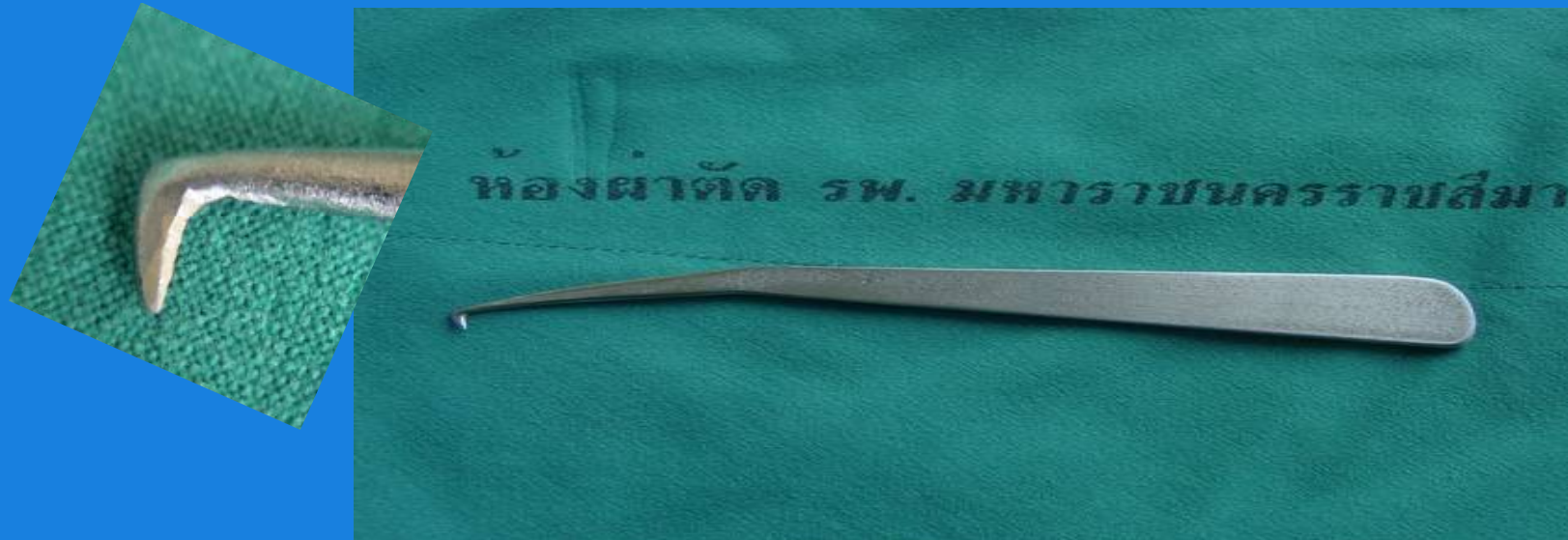

Percutaneous release

- Use in outpatient department
- Success rates are over 90 %.*
- Several method using various instruments have been reported, such as needle no. 19 or Push knife.
- Complications are rare but include tendon or digital nerve injury, hematoma, and persistent pain. *



Korat-Satja1 (KS1) Instrument



- Made out of stainless steel, withstanding common sterilization procedures.
- Not to be bend or fail during the release procedure.



Objective:

- To describe a safe and easy percutaneous trigger finger release using KS1 instrument.
- To evaluate the short-term results and possible complications of percutaneous trigger finger release using a KS1 instrument.



Patients and Methods

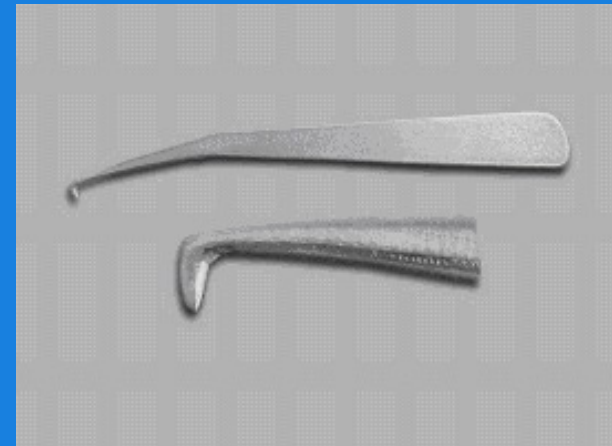
- Trigger finger
- June 2004 – August 2005

Exclude criteria:

Trigger thumb, rheumatoid, and gout.

Trigger finger stage I, stage IV

Approved by ethics committee





Trigger finger
20 patients, 31 digits

Excluded
2 Trigger thumb
2 stage I trigger finger

**Percutaneous release
With KS-I**

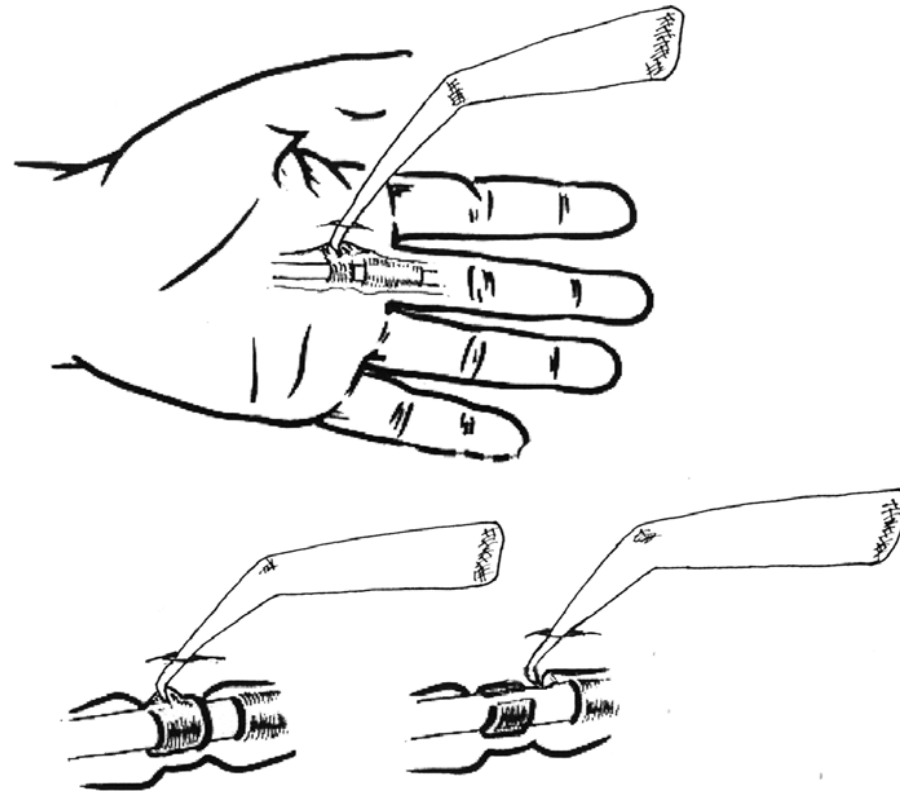
Open technique

**Completed A 1 pulley ?
Nerve, Tendon injury ?**

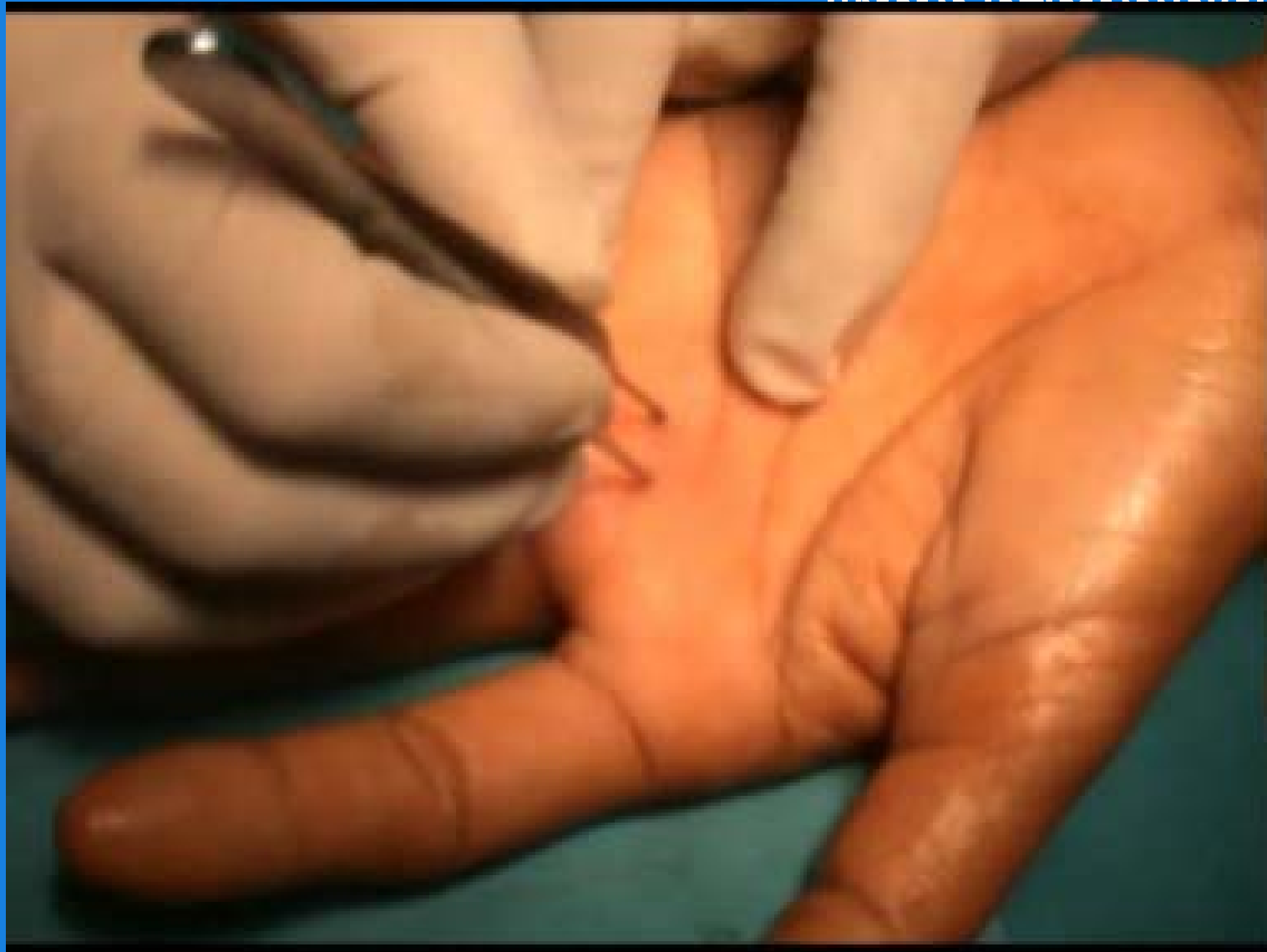**Follow up clinical outcome
at 10 day**

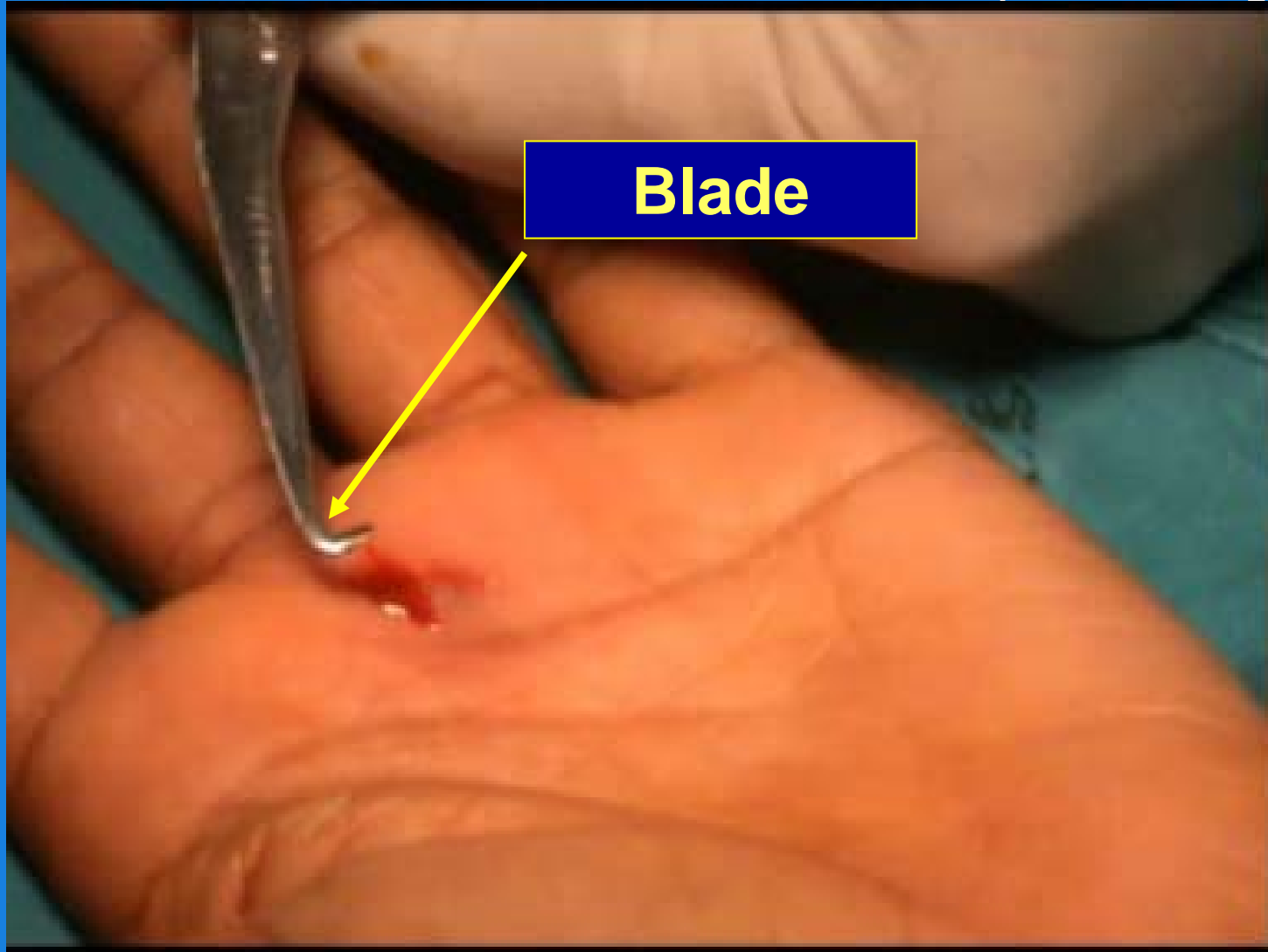


Operative Technique

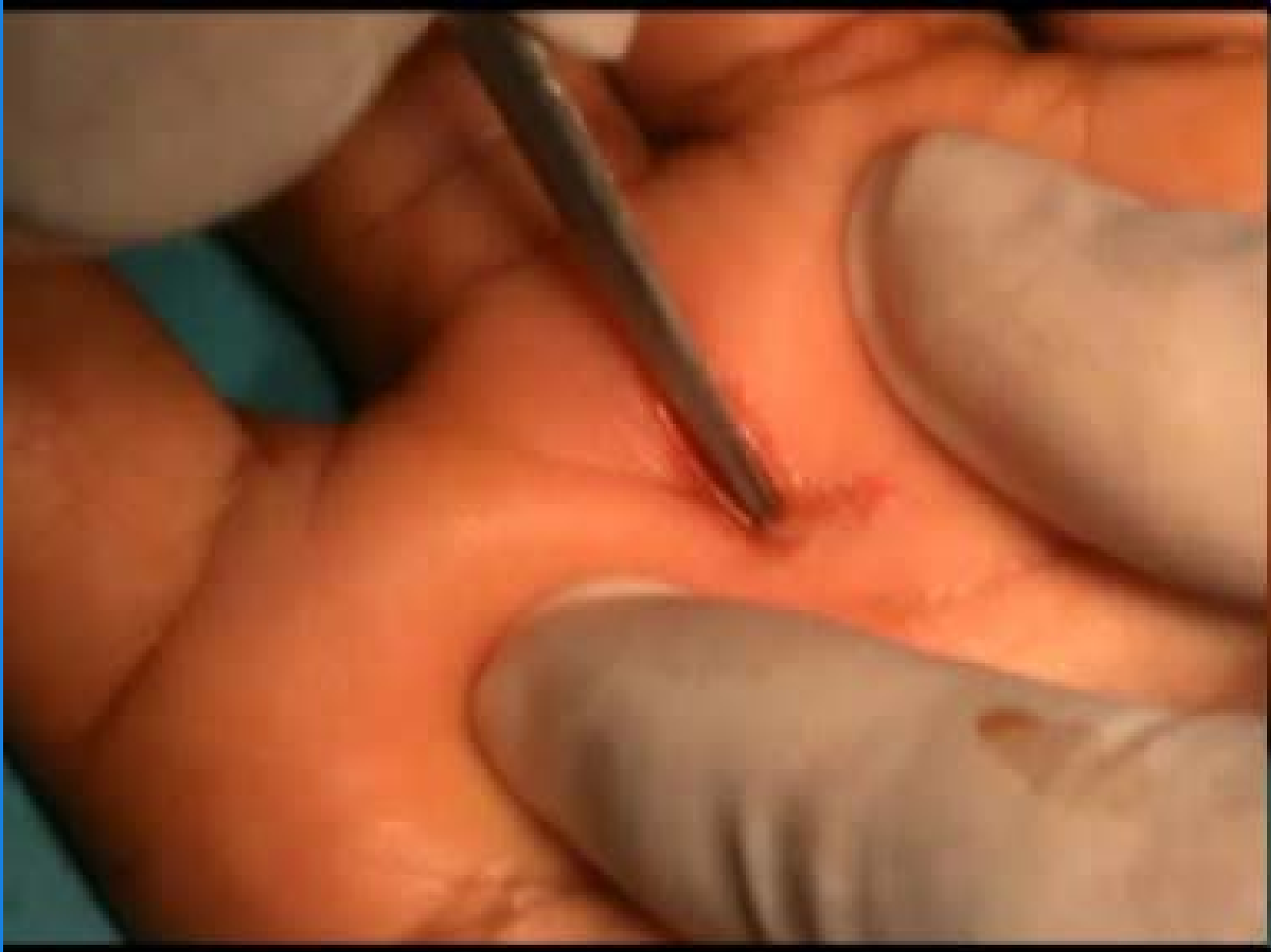

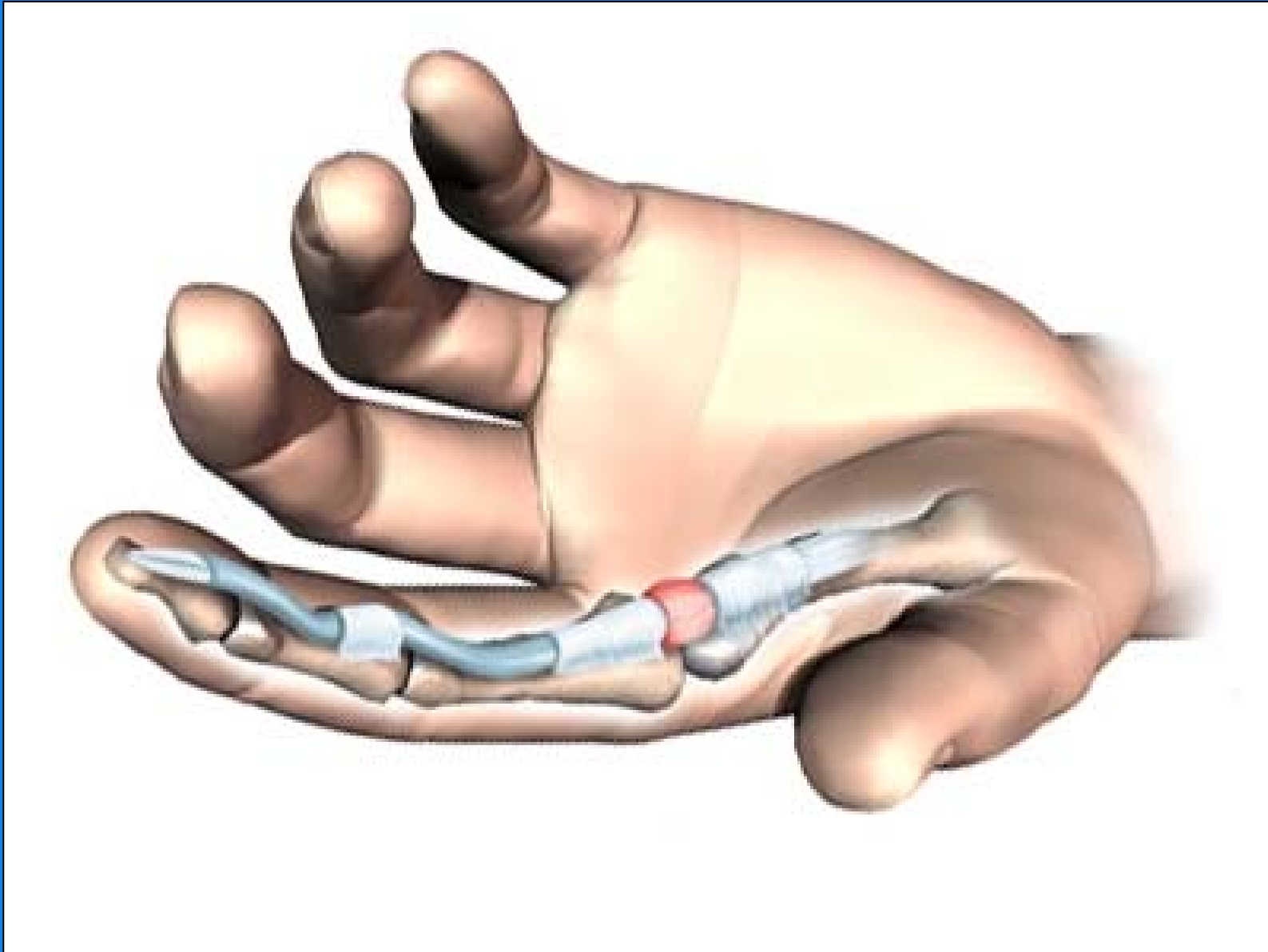
'feel and pull' technique

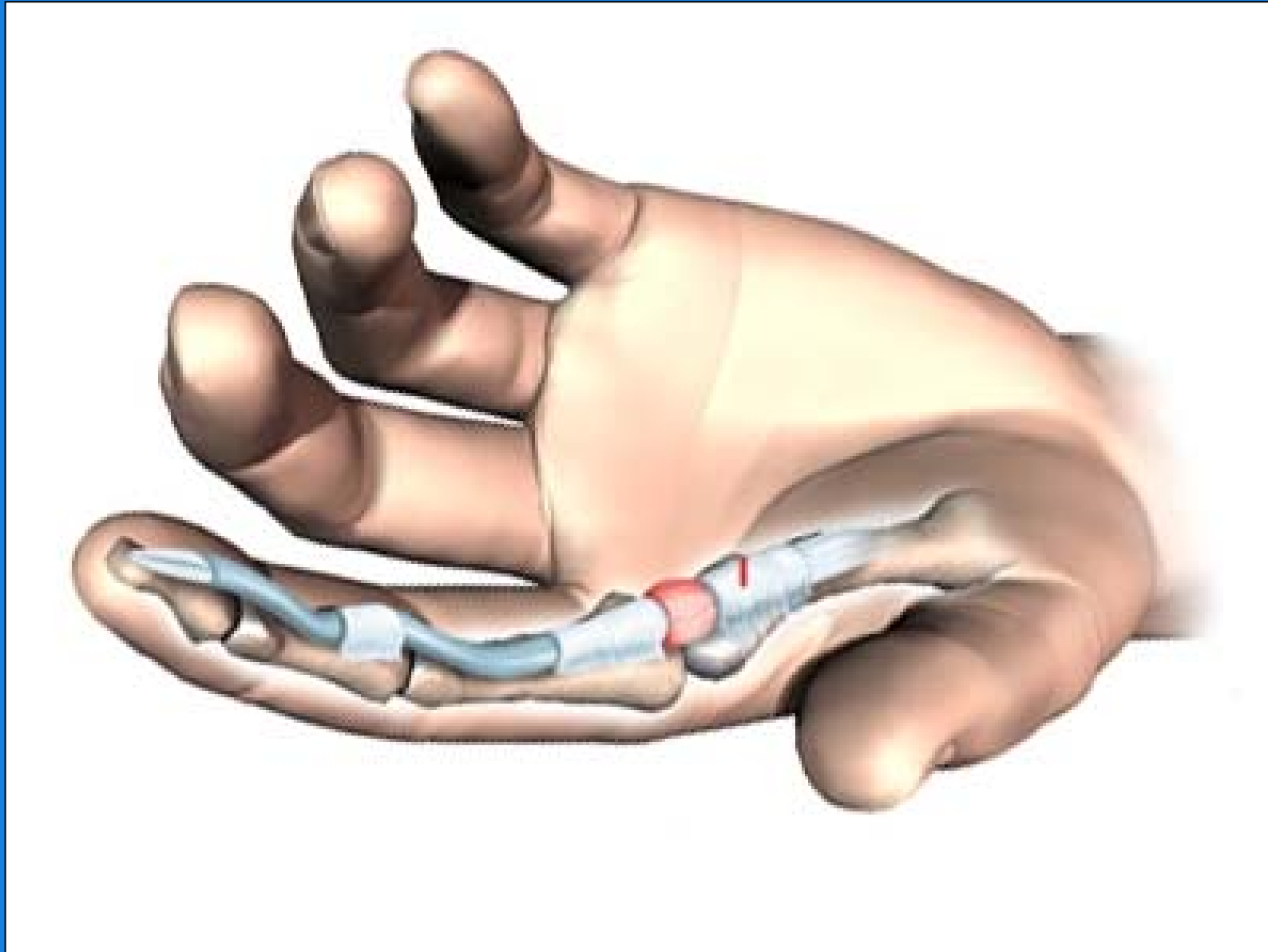


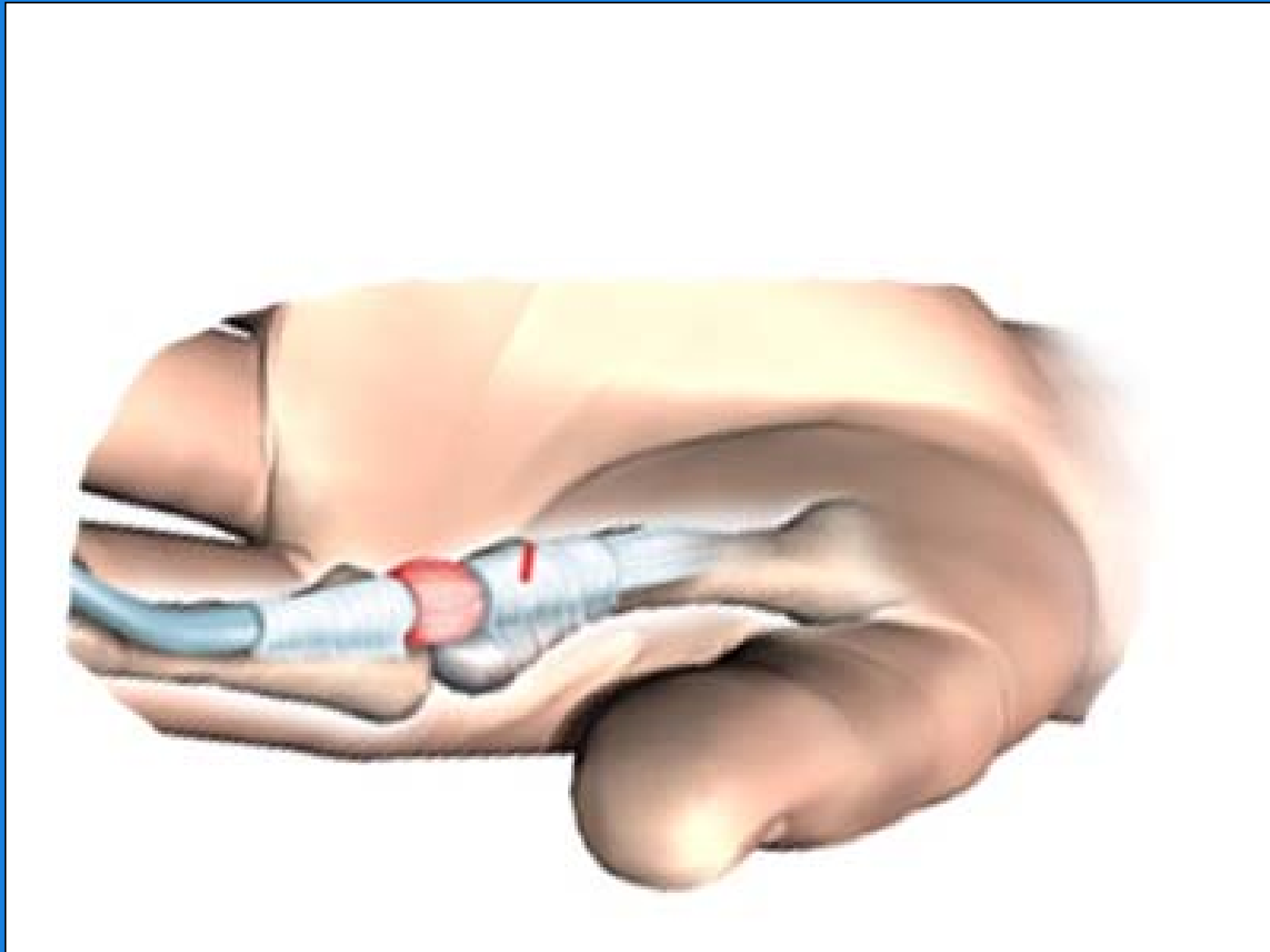

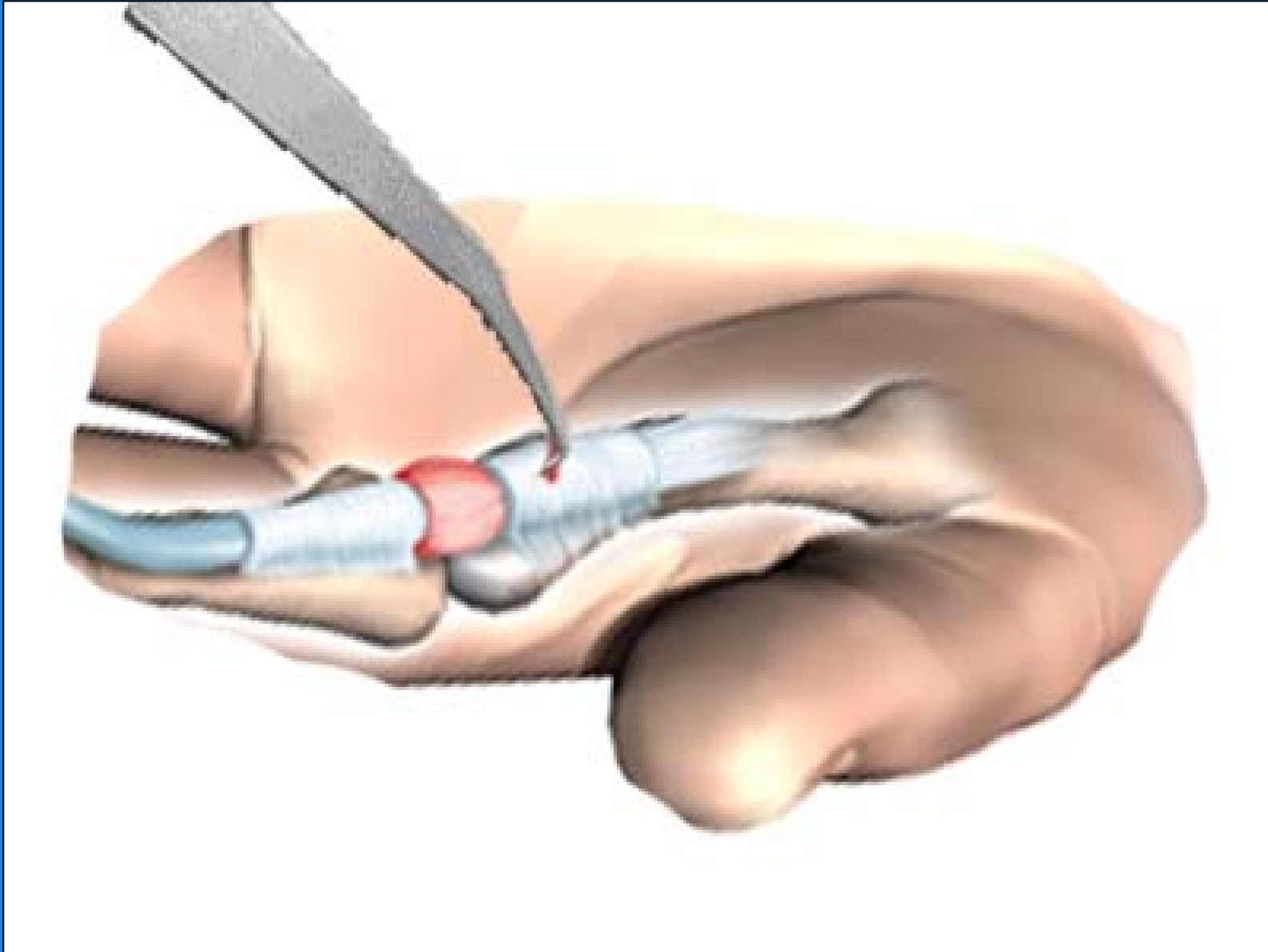
Blade

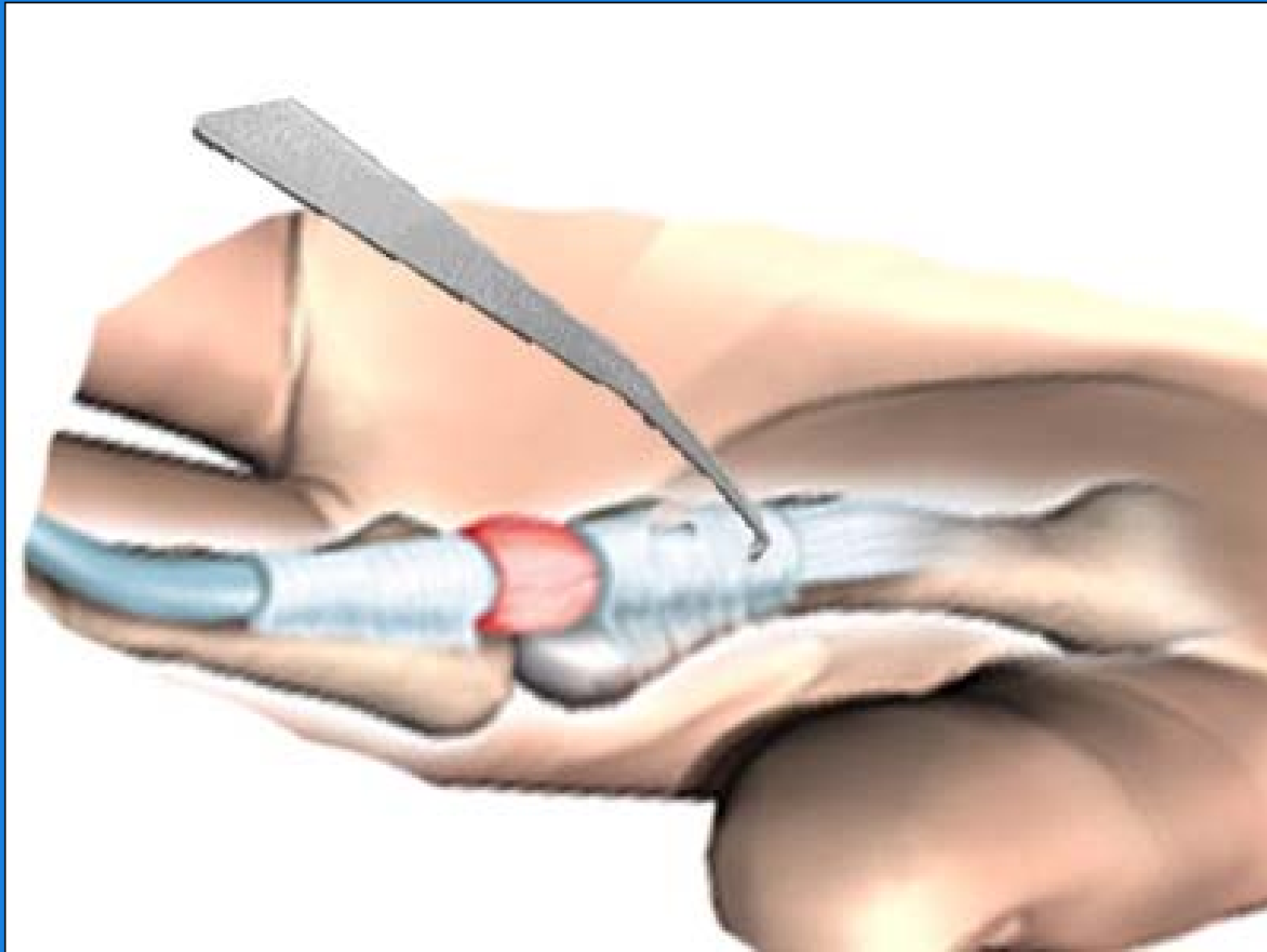


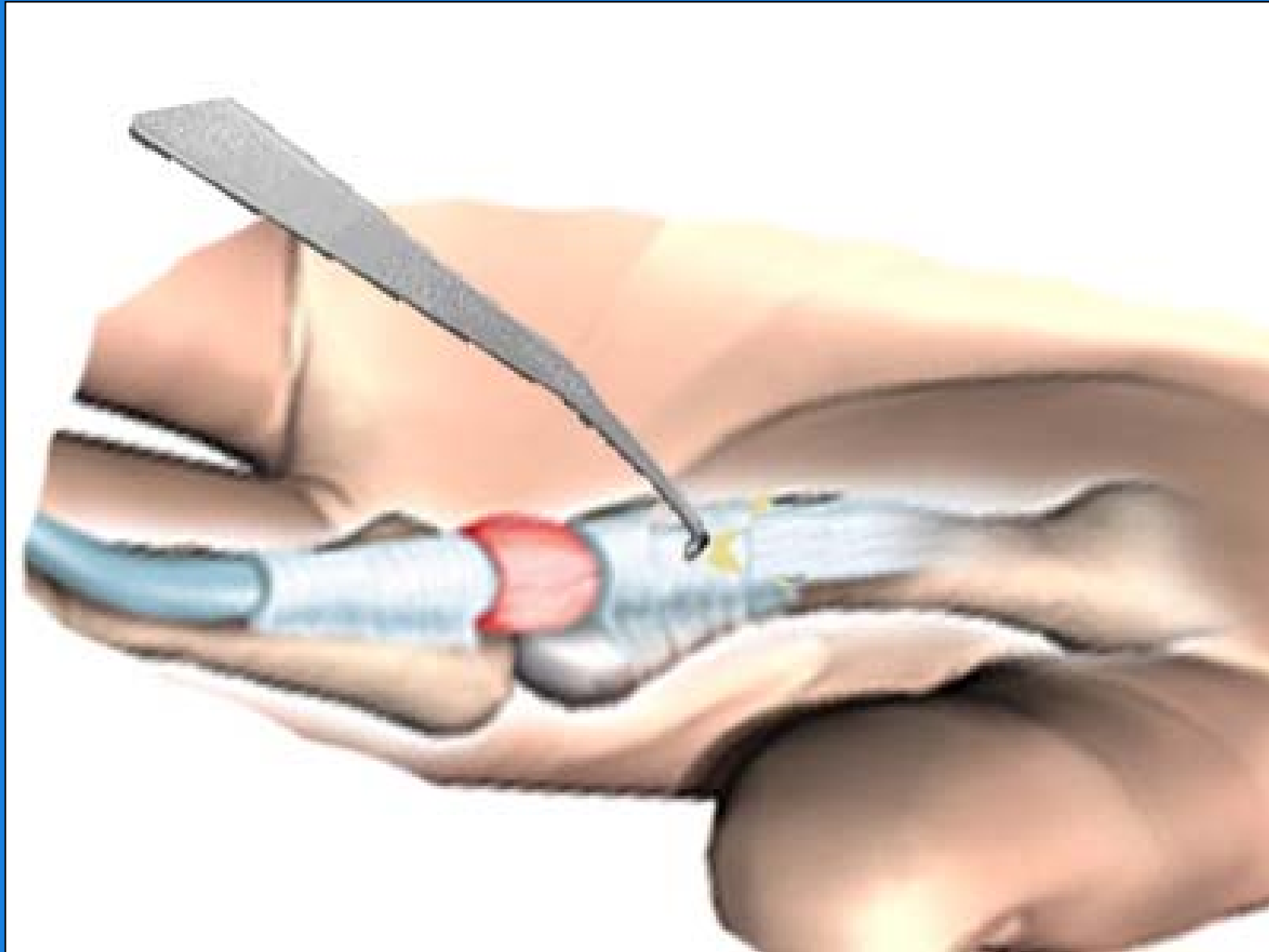


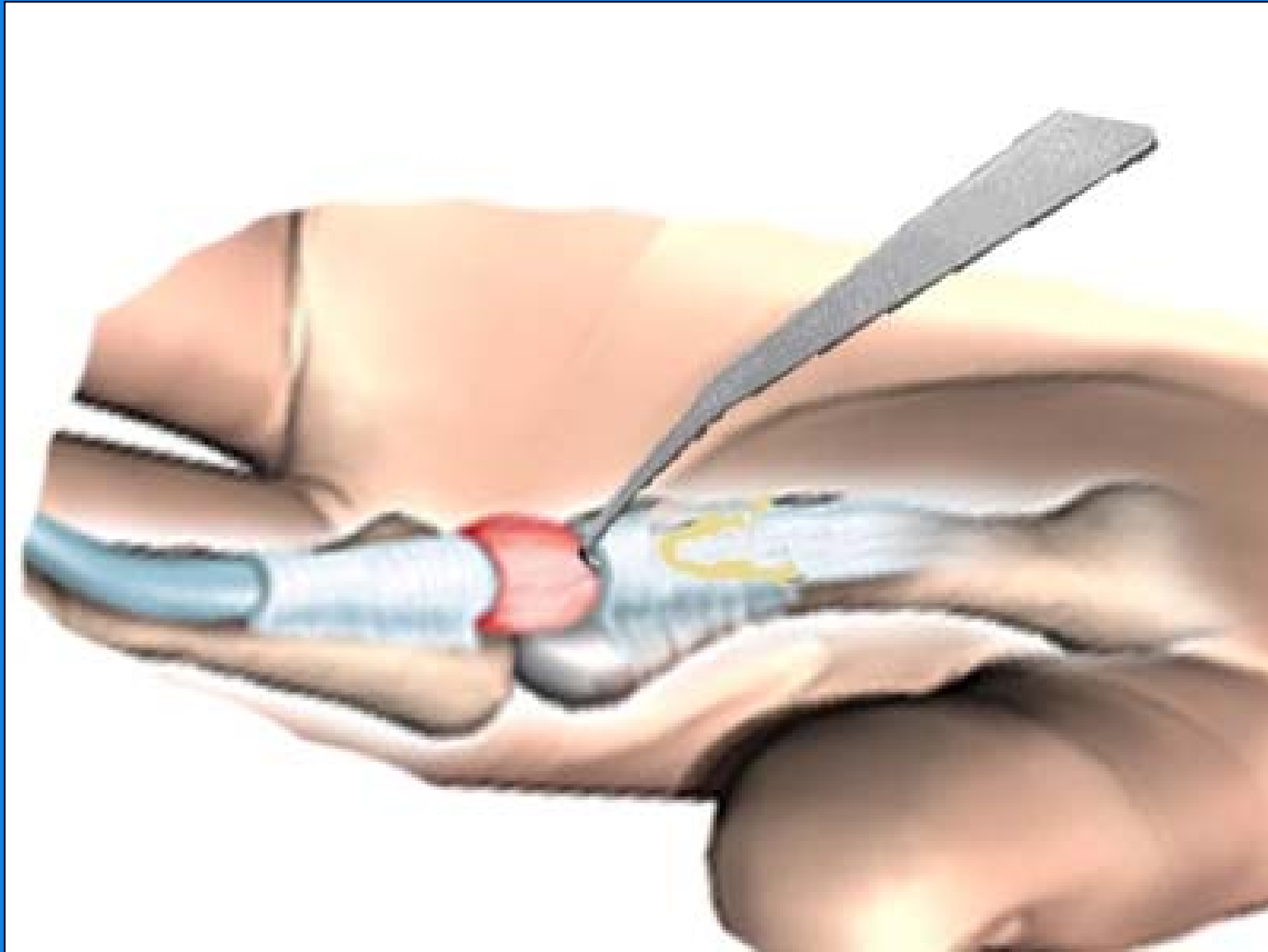

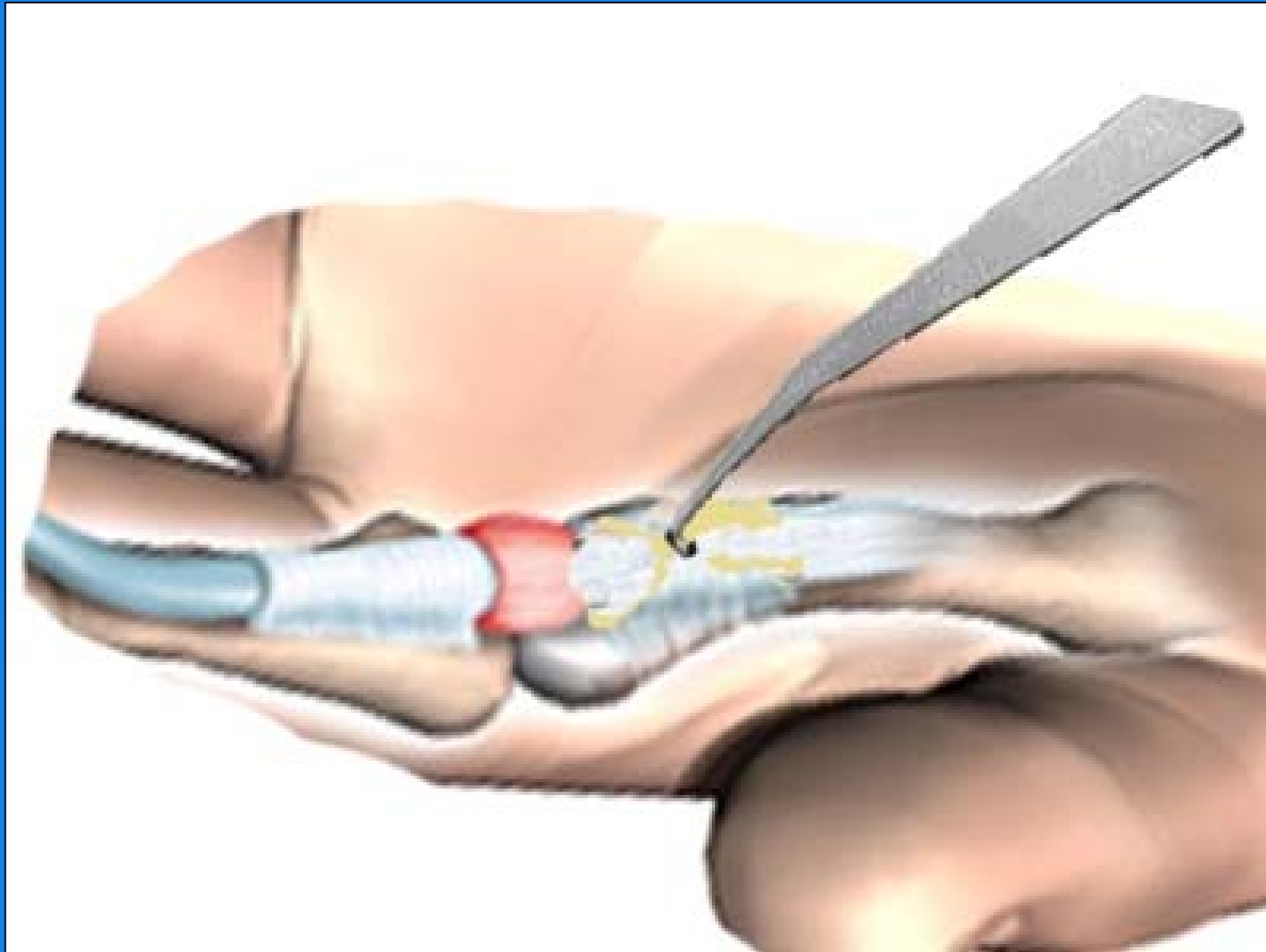


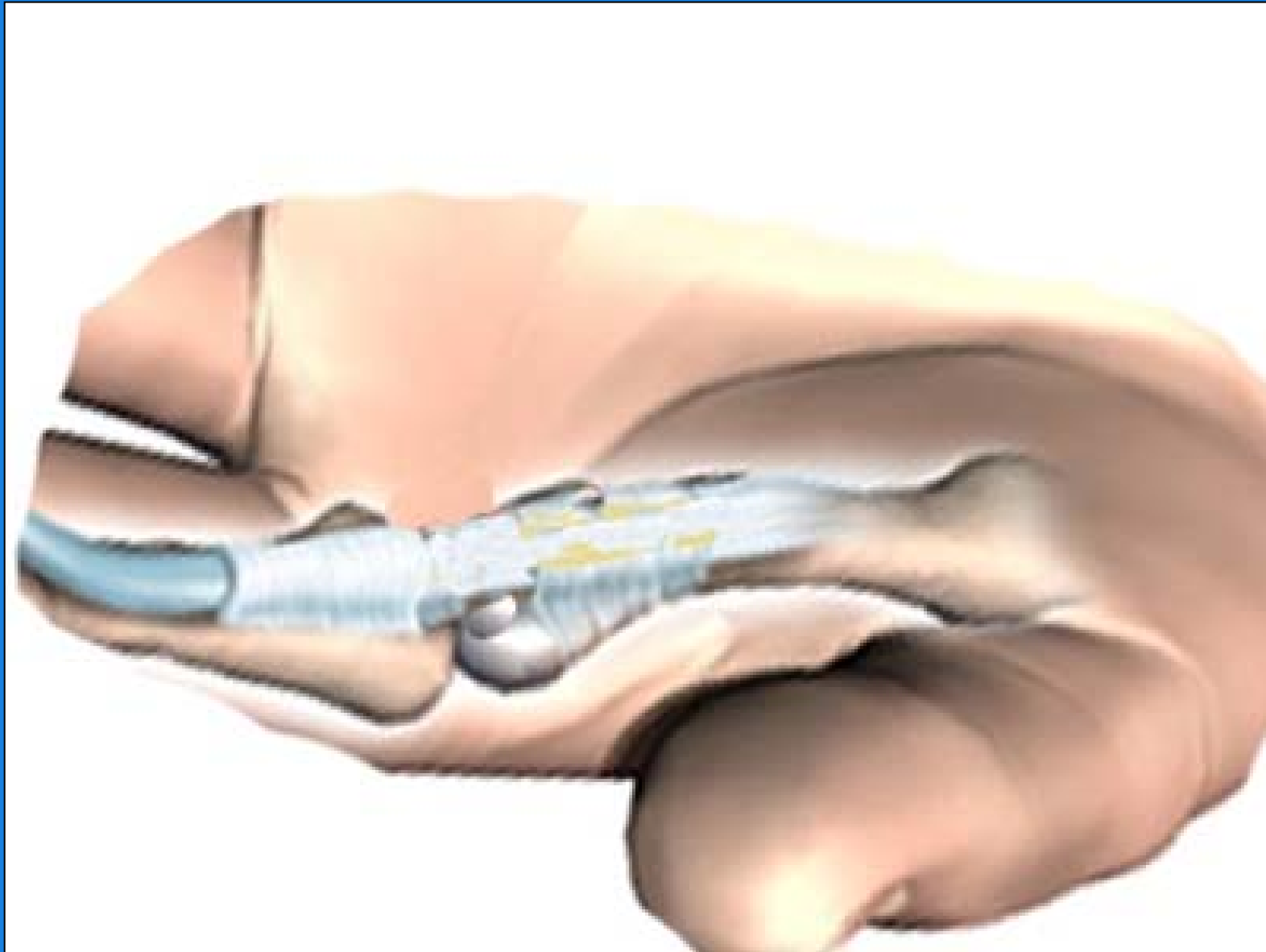





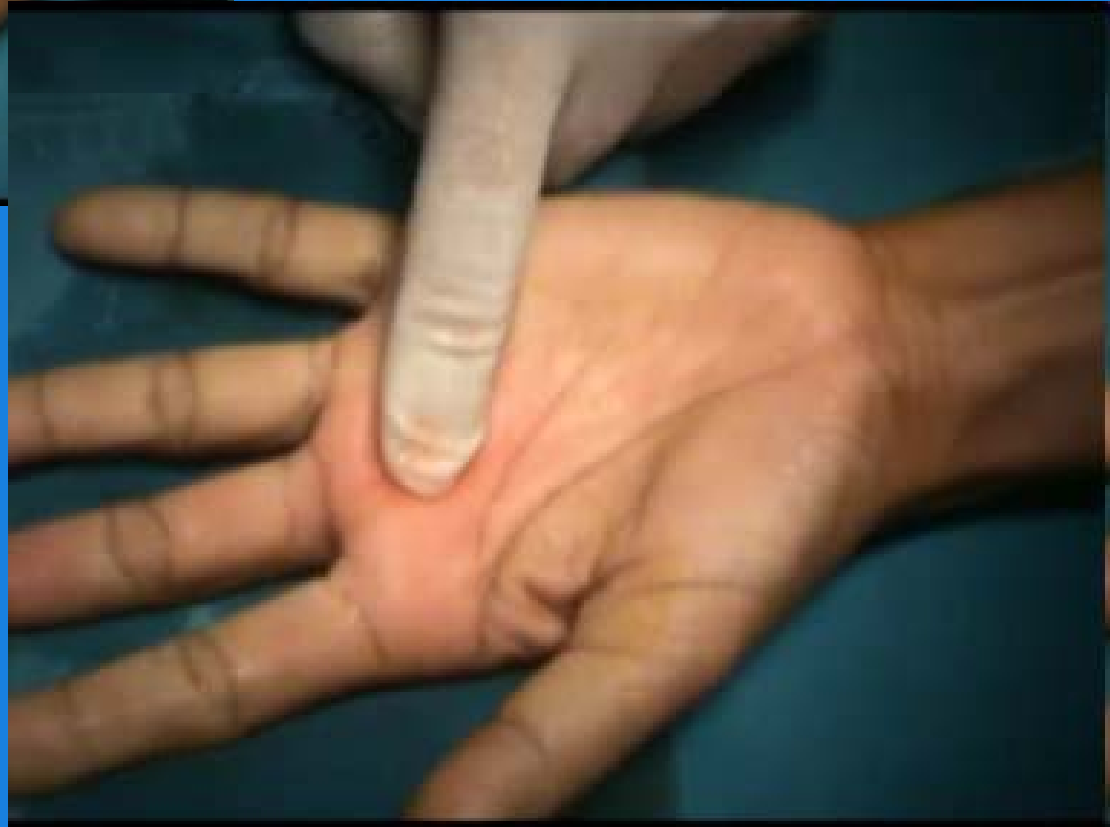
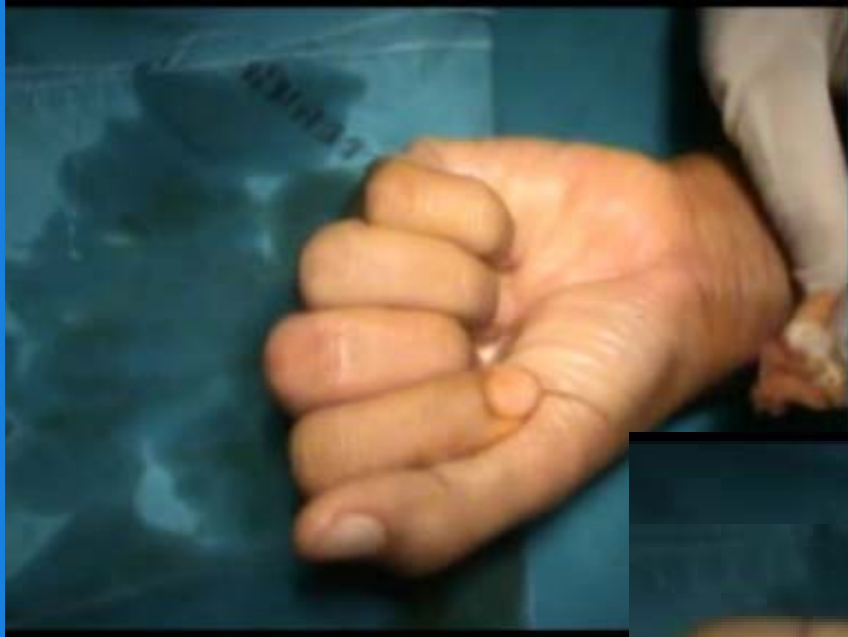





orthopaedics surgeon
maharak nakhonratchasima





Result

- Mean age 50.4 years; Range 34 to 75 years.
- 16 females, 4 male.
- Mean duration of symptoms before treatment 11.8 months (2 months - 3 years)
- 10 patients had previous steroid injection.



Result

- 20 patients, 27 trigger digits, stage II or III.
 - The index was involved in 5
 - The long finger in 14
 - The ring finger in 8.



Result

- All A1 pulley were released by KS-1
- No Tendon, digital nerve, A2 pulley injury



Result


At the 10 days after operation follow-up.

- Triggering and pain were eliminated in 26 fingers postoperatively (93.1%).
- In one case, re-triggering 10 days later.



Discussion

Gilberts EC , int surg 2002

- **Prospective study**
- 100 pt
- percutaneous release vs open release
-  **time, cost, pain**
- **no failure, no complications**



Discussion

Kilic BA , Acta Orthop Traumatal Ture.2002

- **needle No.16** → open release
- complications:
 - **superficial abrasion of tendon**



Discussion

Michael JD and Pen GM: J Hand Surg (Am)
1999

- new **push knife** vs 19-gauge needle
- 12% new push knife ; **A2 pulley injury**
- 0% 19-gauge needle



Discussion


Current study

- All A1 pulley were released by KS-1 instrument
- **93.1%** short term good result
- No Tendon, digital nerve, A2 pulley injury



Conclusion

- Percutaneous trigger finger release using **Korat-Satja1** is a easy, safe and effective procedure with a low rate of complications.



orthopaedics surgeon
maharak nakhoratchasma



Thank you for your attention

orthopaedics surgeon
maharaj nakhonratchasima

